BEFORE TREATMENT

CASE NO.20
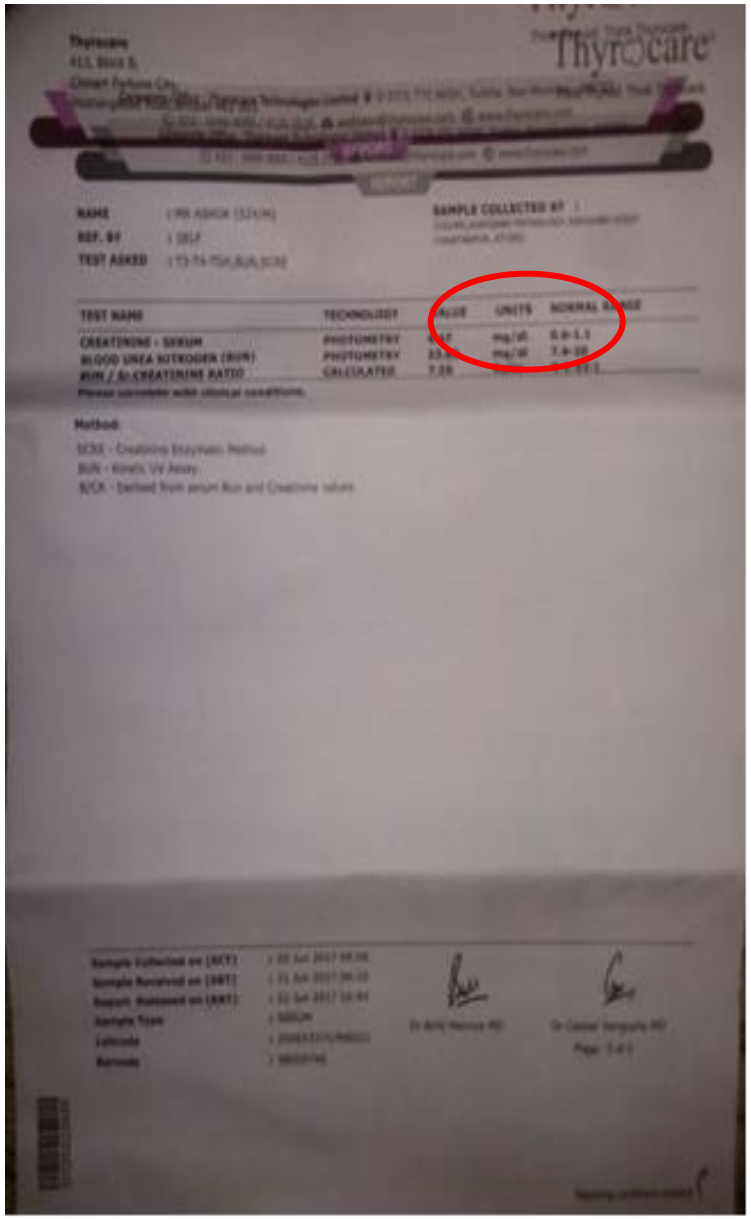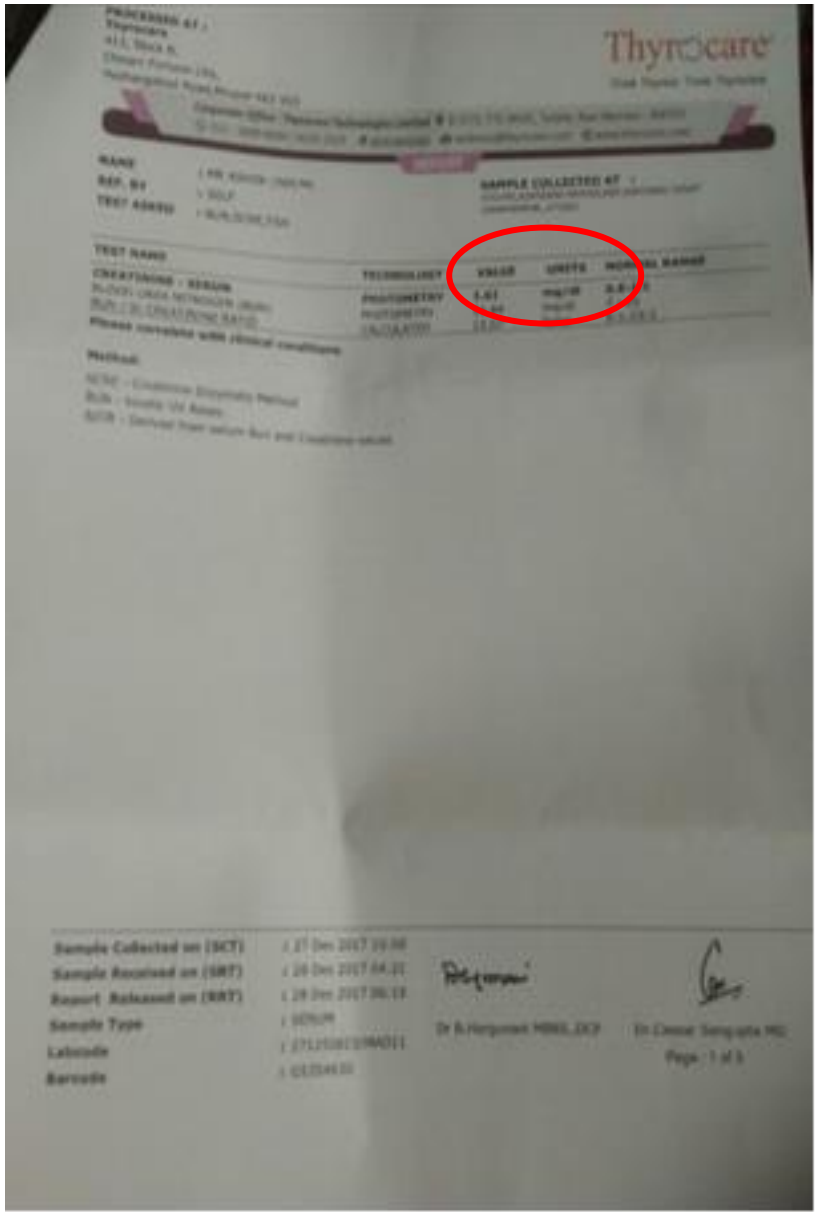
AFTER TREATMENT